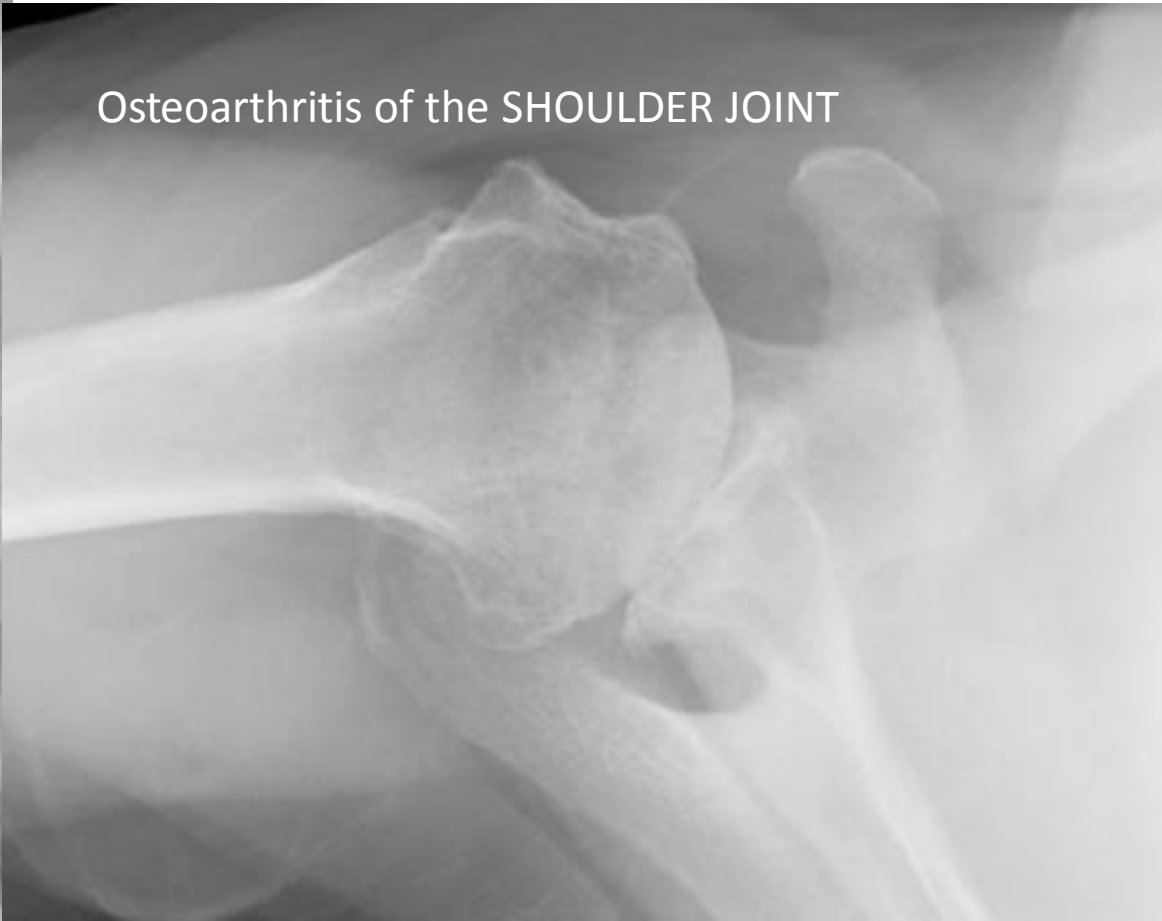
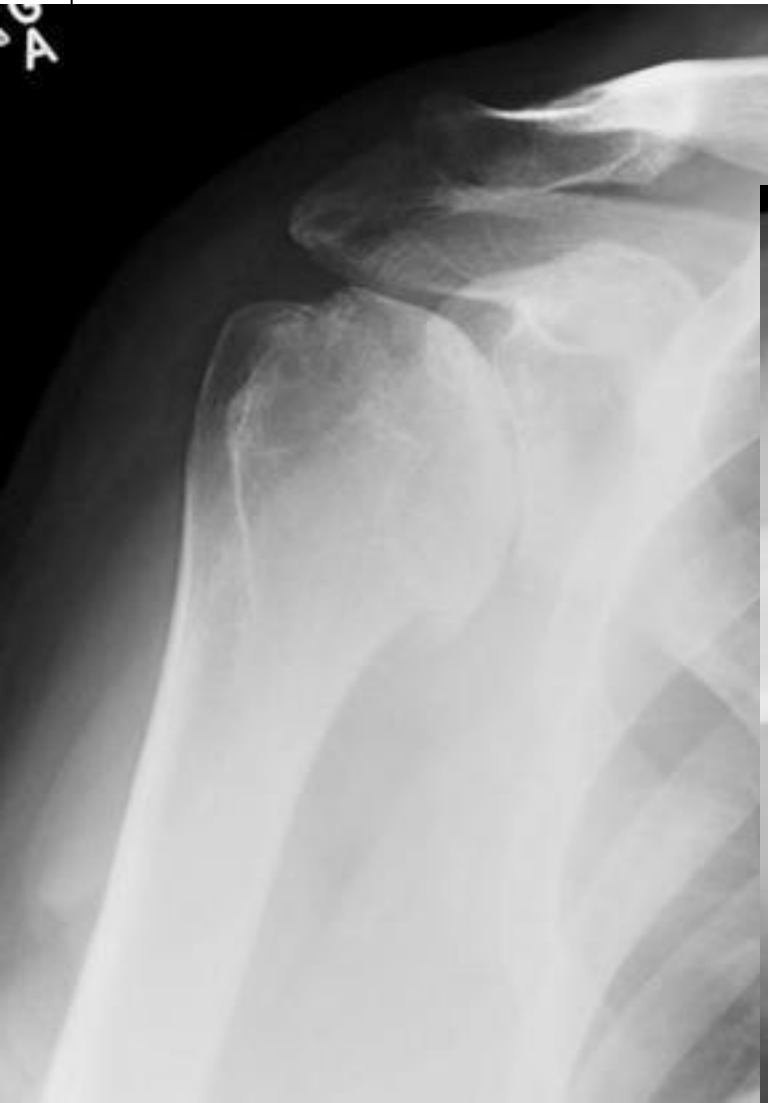
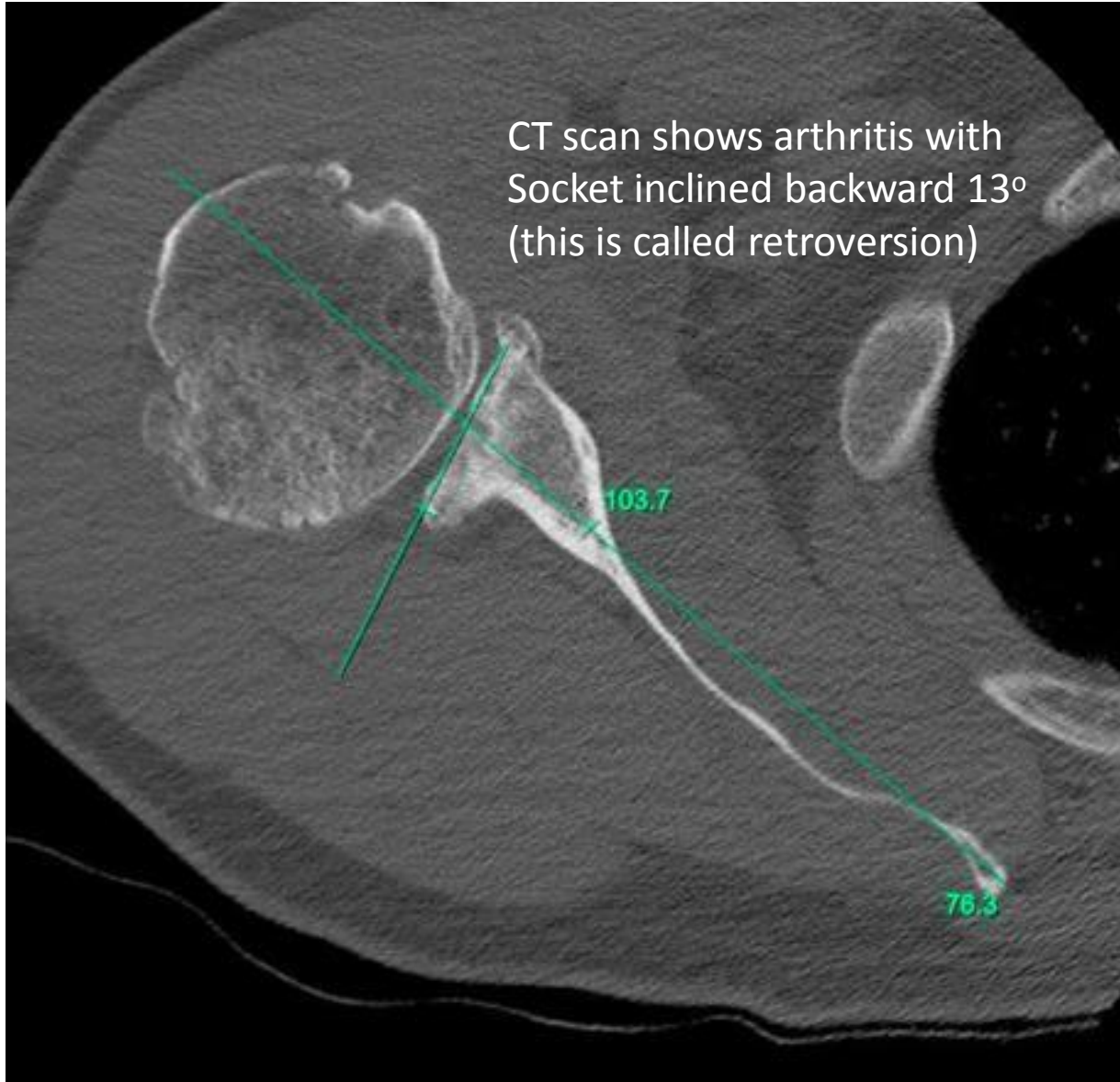58 yo man with chronic Right shoulder pain and Limited motion



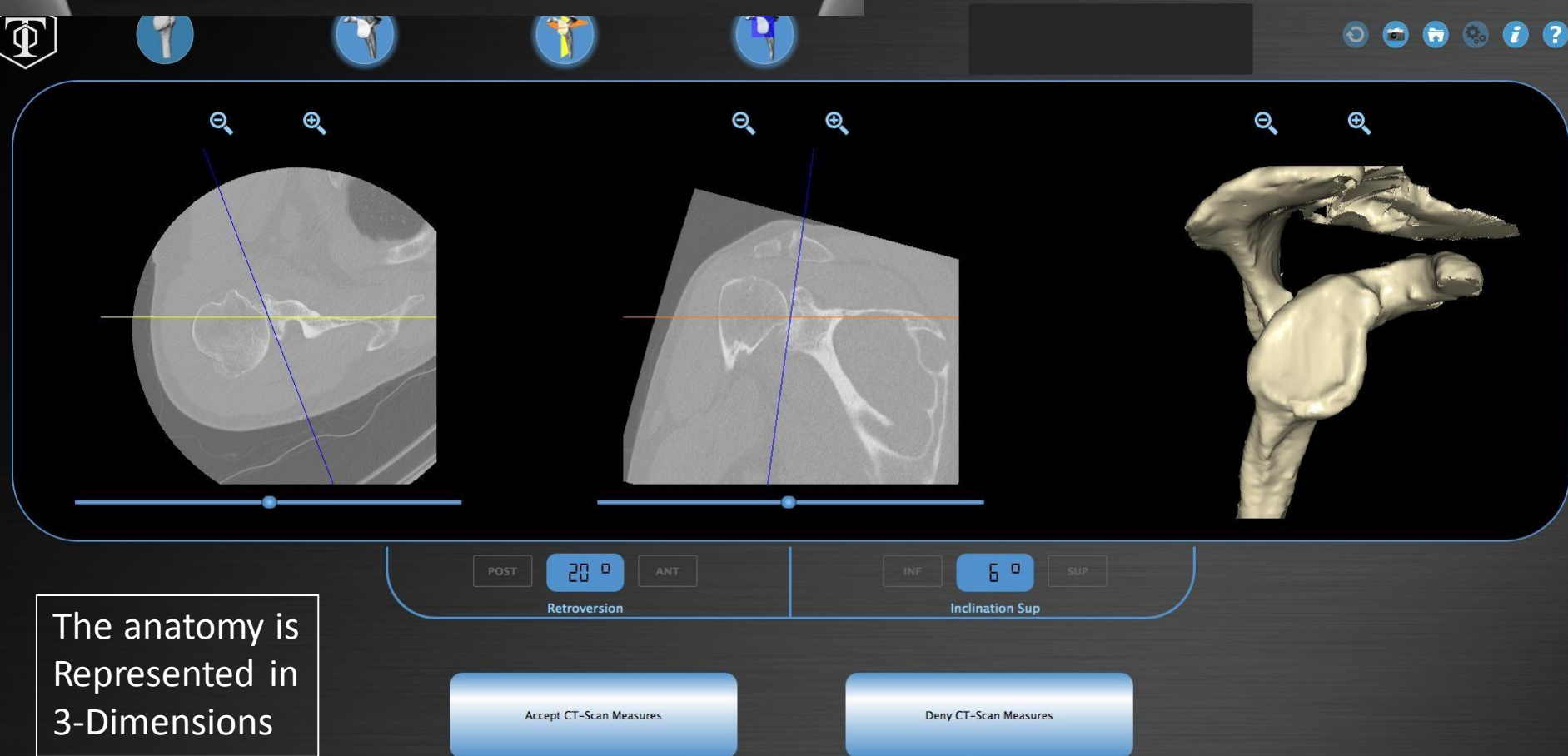
CT scan shows arthritis with
Socket inclined backward 13°
(this is called retroversion)



BLUEPRINT 
3 D PLANNING + PSI

TORNIER 

3-Dimensional Planning allows the Surgeon to create a model of The shoulder and perform the Operation virtually on a laptop Before doing so in the patient



The anatomy is Represented in 3-Dimensions

Glenoid

Orientation

21°

Direction

POST

Humerus

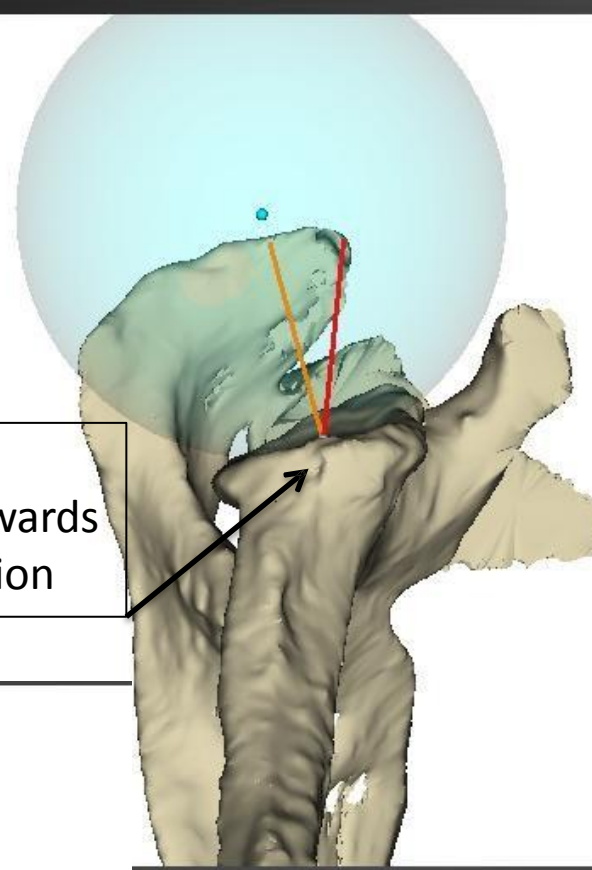
Subluxation (%)

81

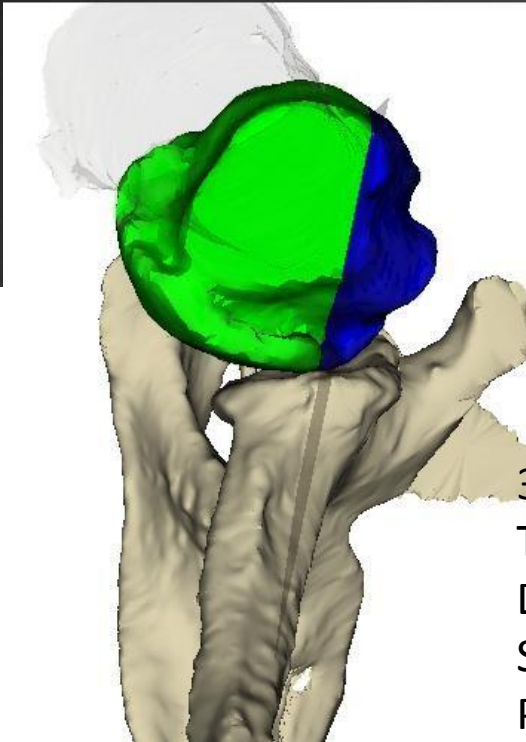
Direction

POST

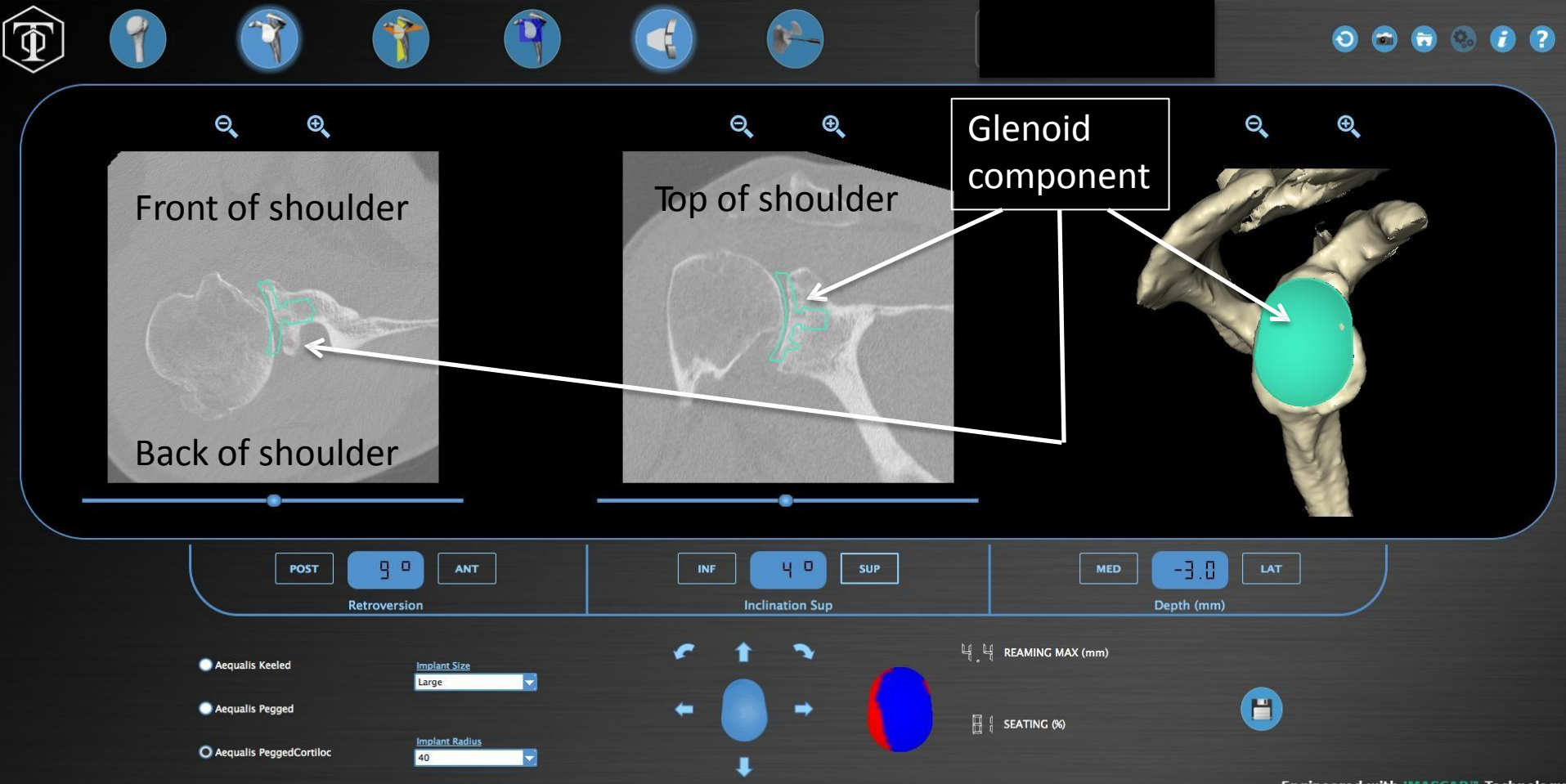
The socket is
Inclined backwards
Into retroversion



Angle between the Glenoid centerline and the transversal axis



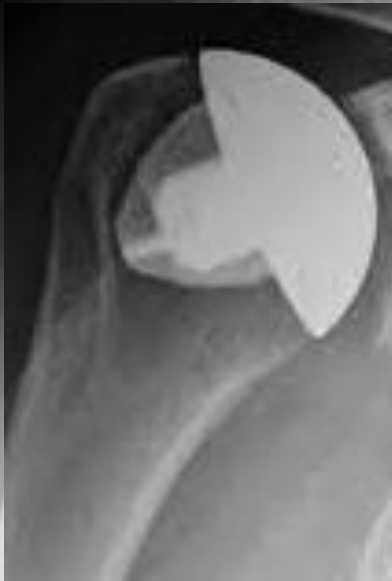3-Dimensional planning demonstrates
That the humeral head (ball) is
Displaced out the back of the
Socket (posteriorly) 81% (Green area). Centered
Position of the ball would be 50%



The socket can be placed in the optimum position using controls on the computer program So the procedure can be done virtually before doing the actual surgery in the patient. This ensures maximum motion for the patient and durability of the result.

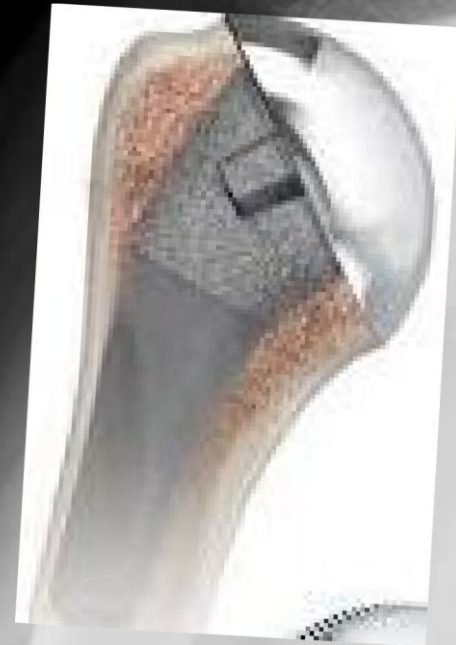The humeral replacement may be without a stem or with a stem.

Stemless advantages



1. Faster surgery
2. Requires strong bone
3. Ingrowth of bone into implant
4. Less steps to complete

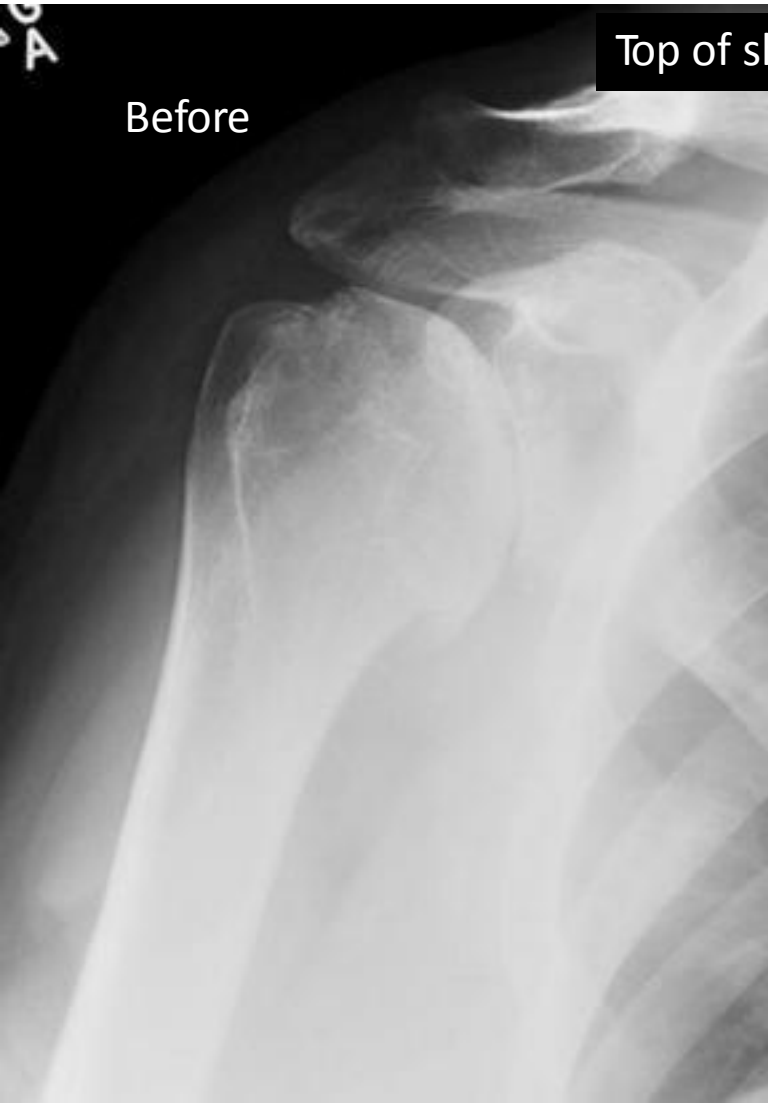Stemmed advantages



1. Better in less strong bone
2. Requires more steps
3. May be cemented in place

CA

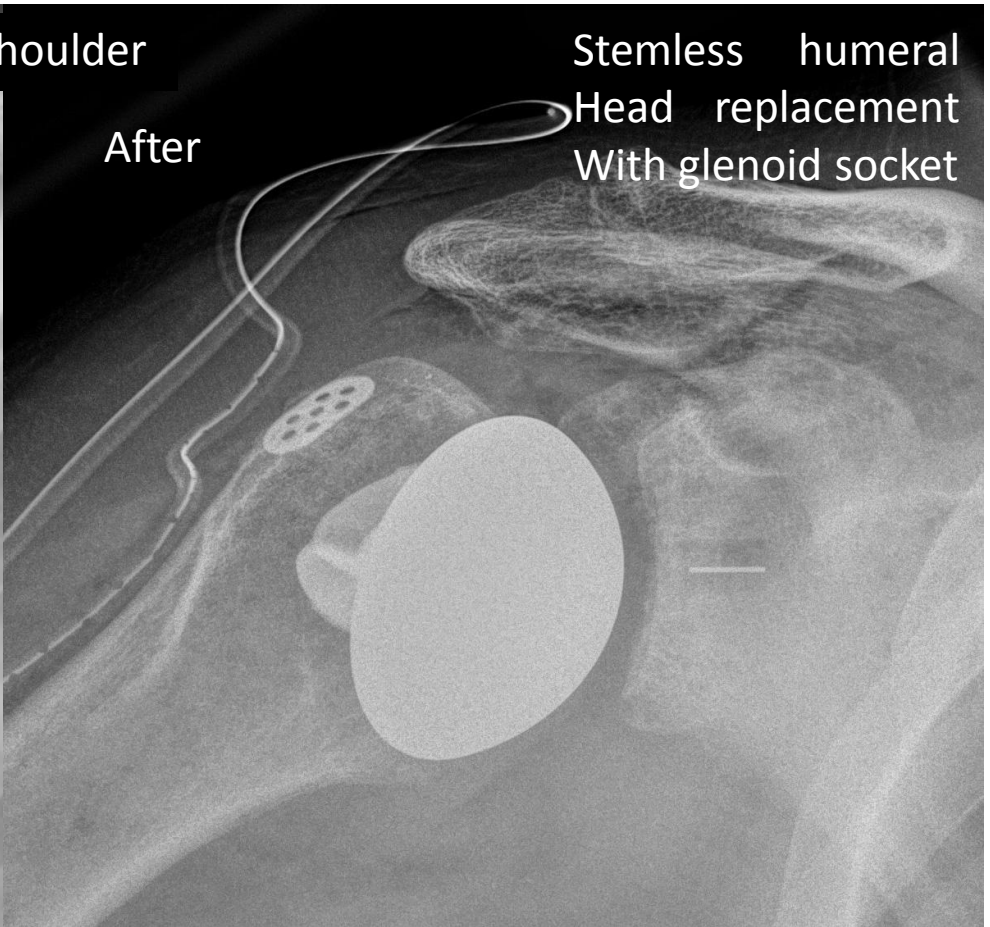
Before



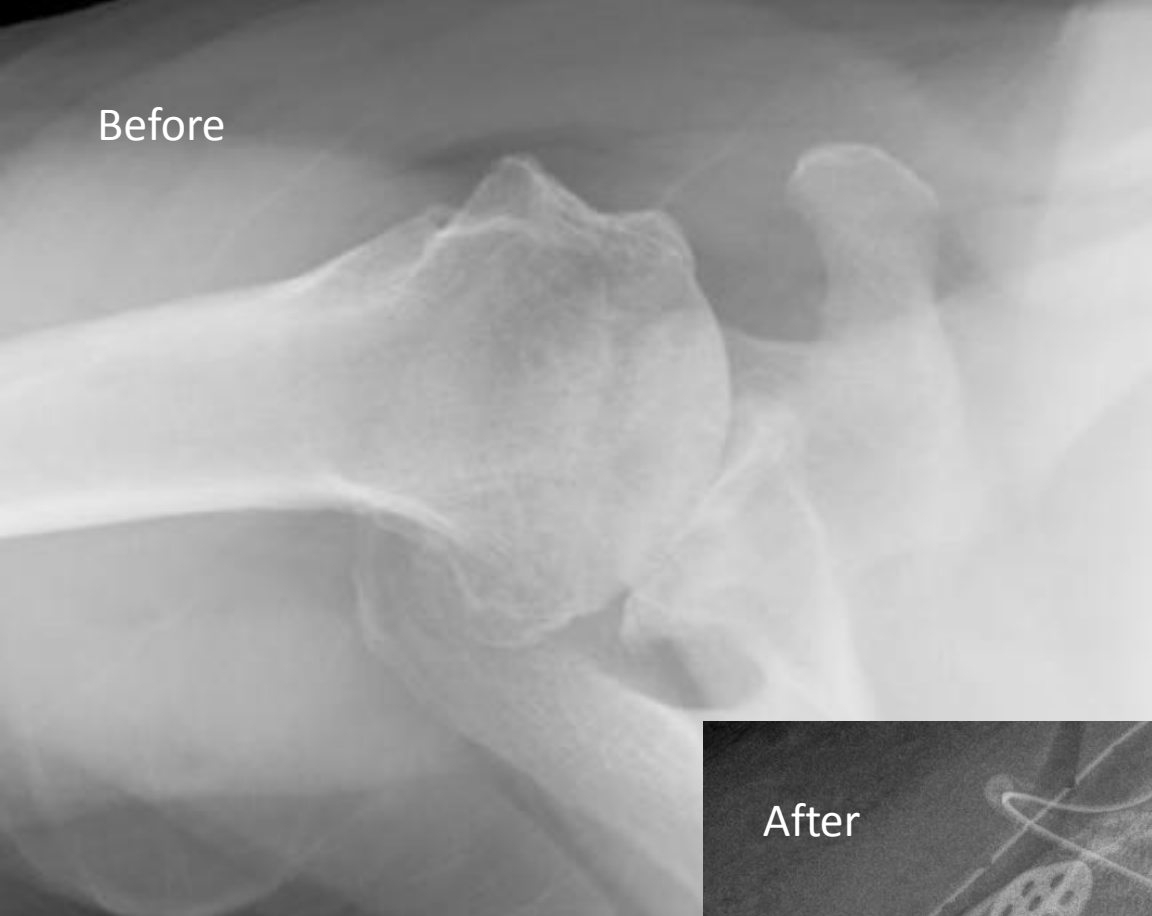
Top of shoulder

After

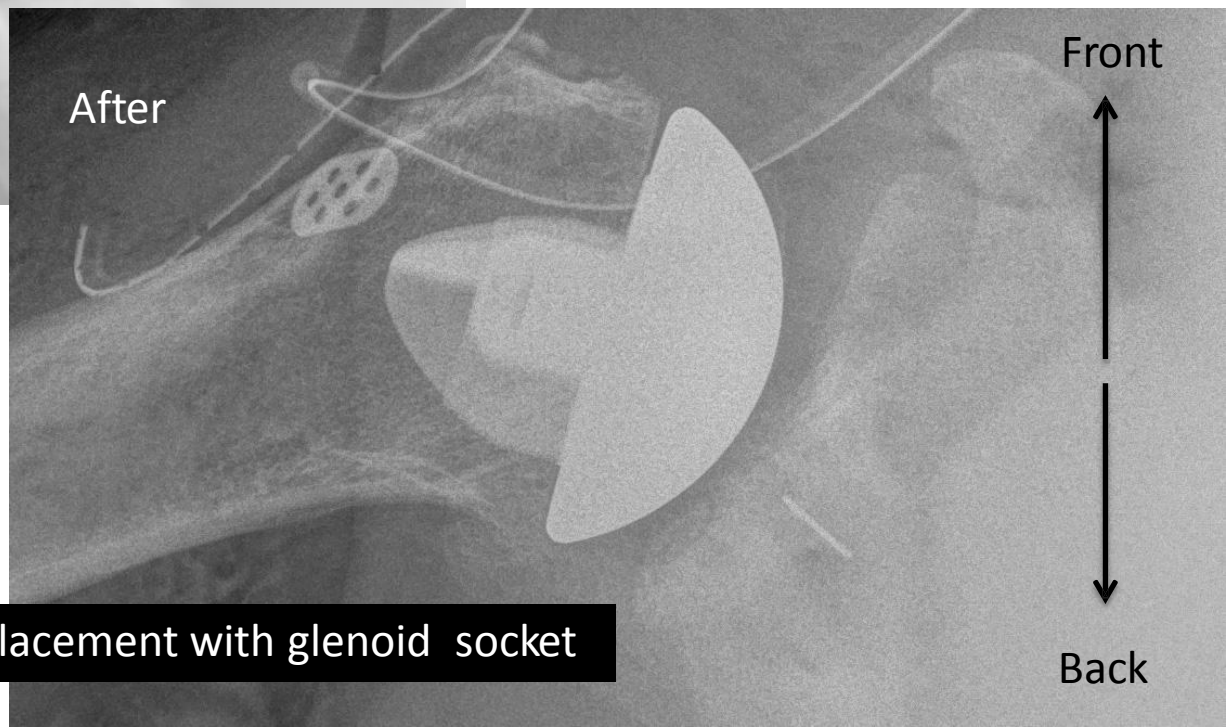
Stemless humeral
Head replacement
With glenoid socket



Before



After



Front

Back

Stemless humeral head replacement with glenoid socket