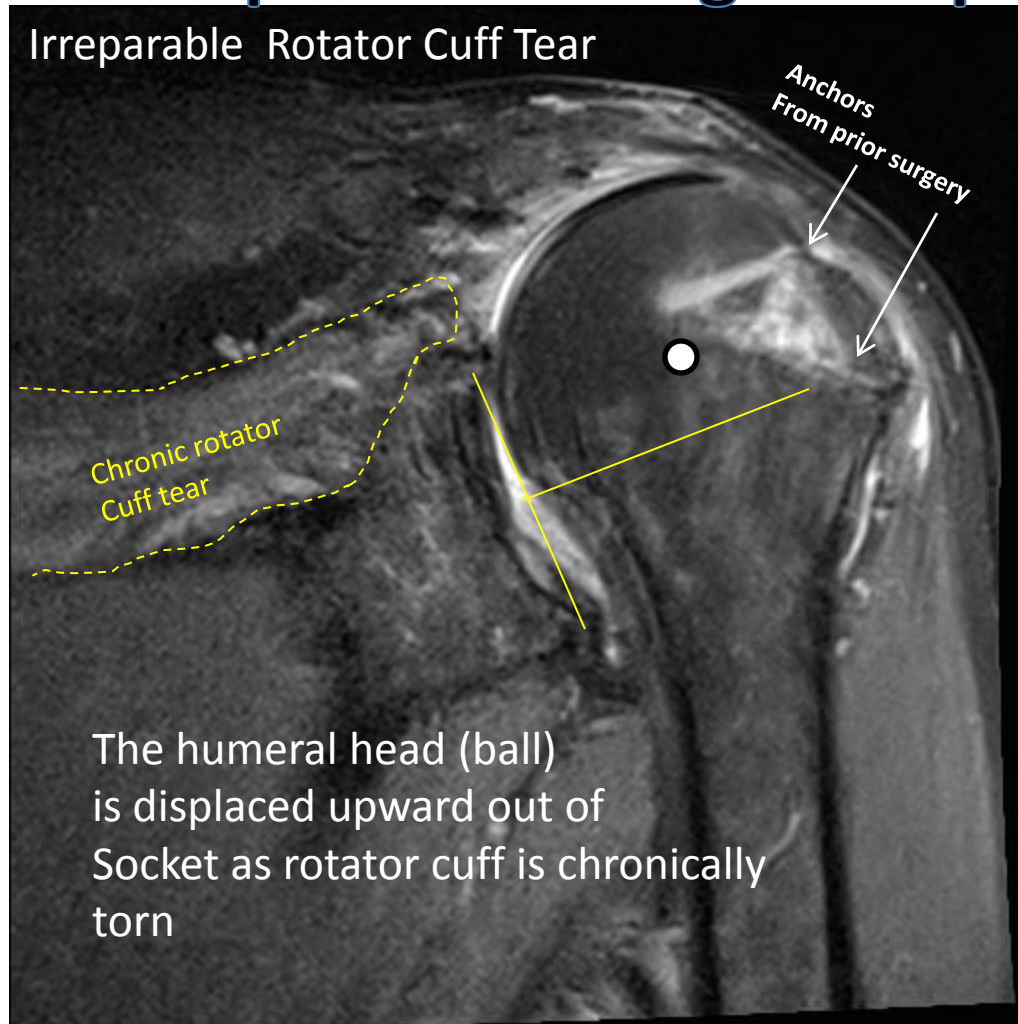


Management of Irreparable rotator cuff tear

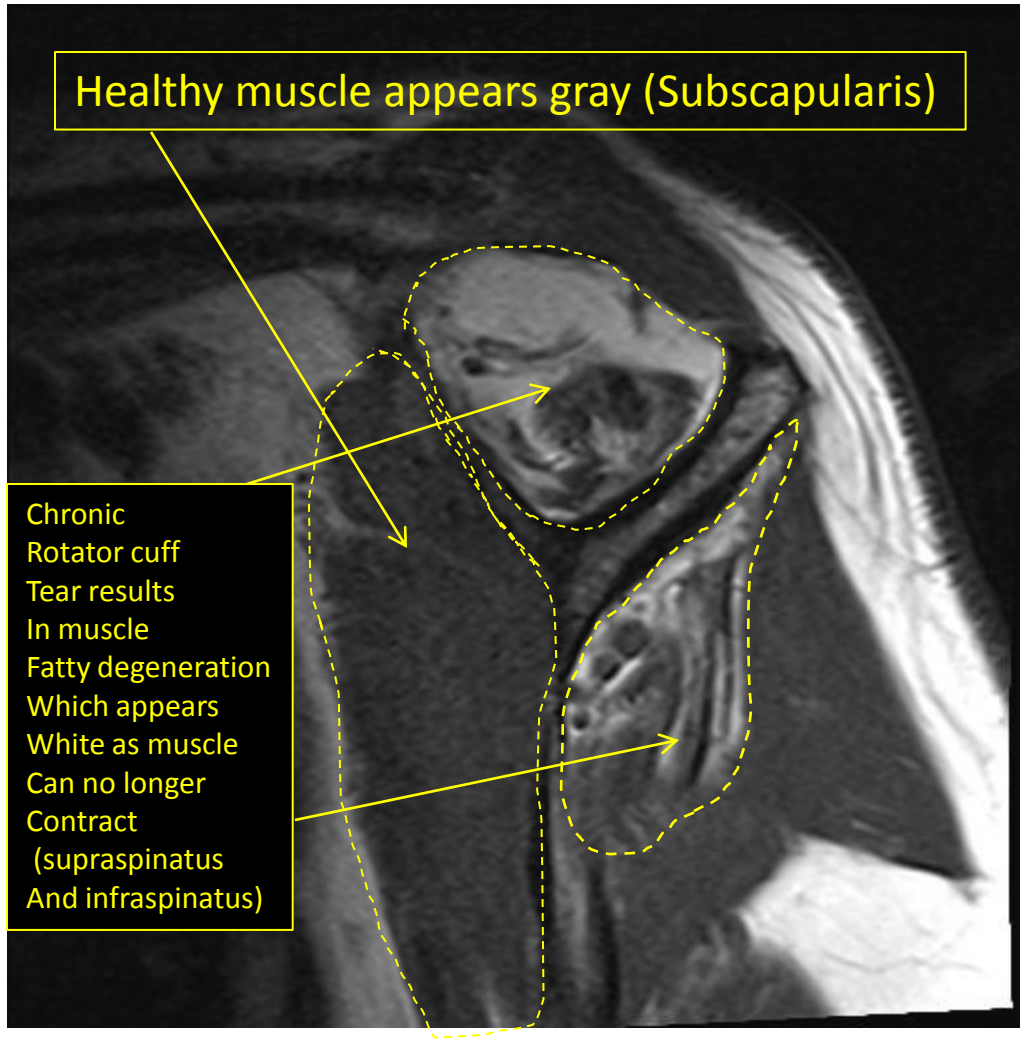
After multiple failed surgical repairs

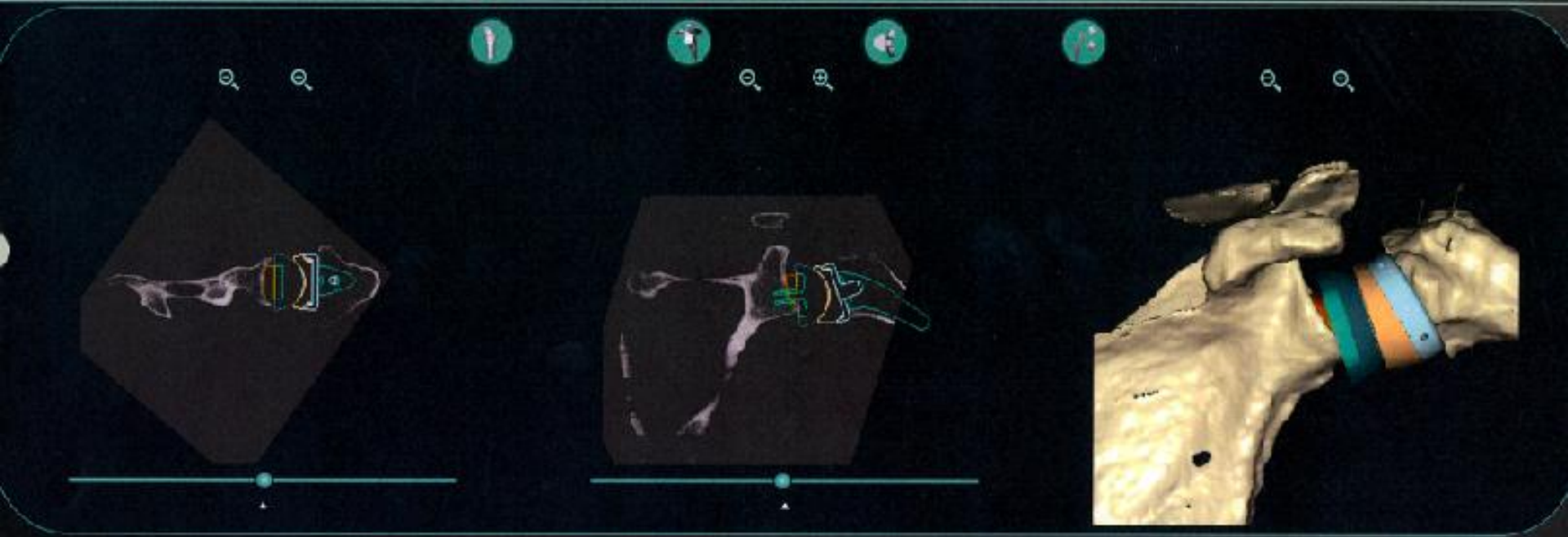
Irreparable Rotator Cuff Tear



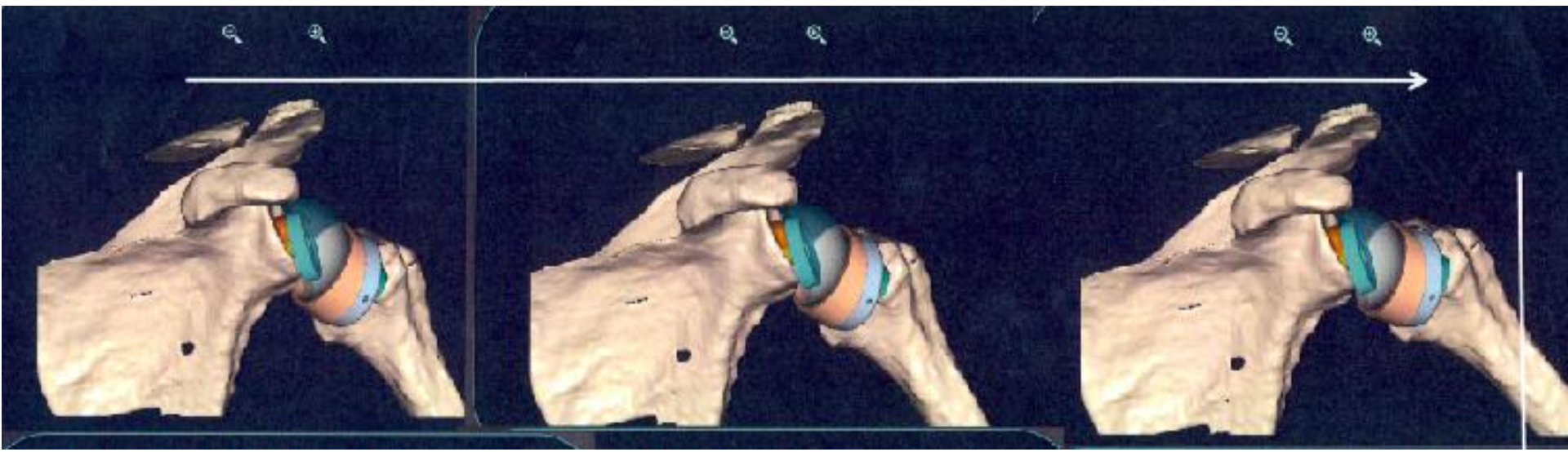
Healthy muscle appears gray (Subscapularis)

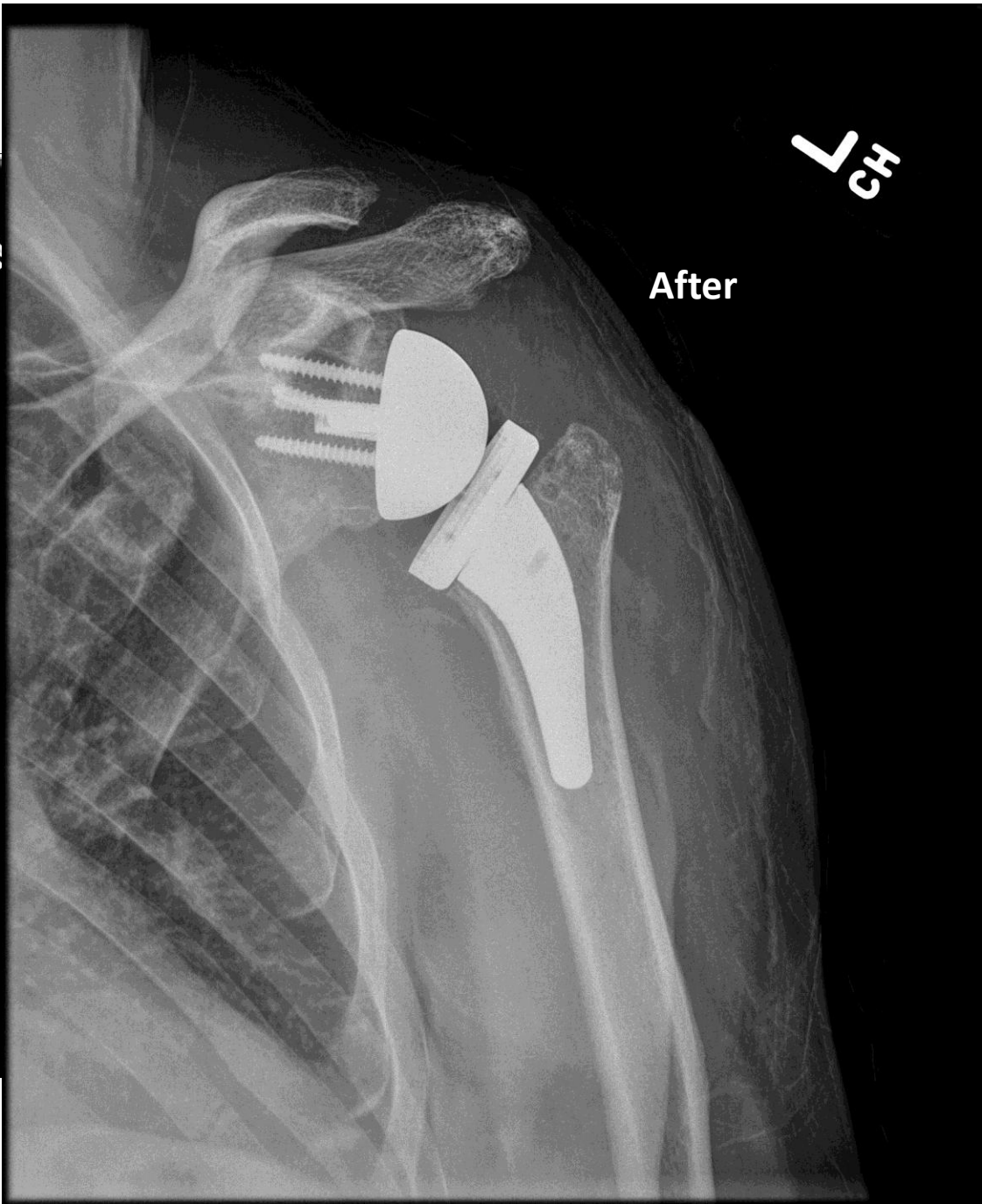
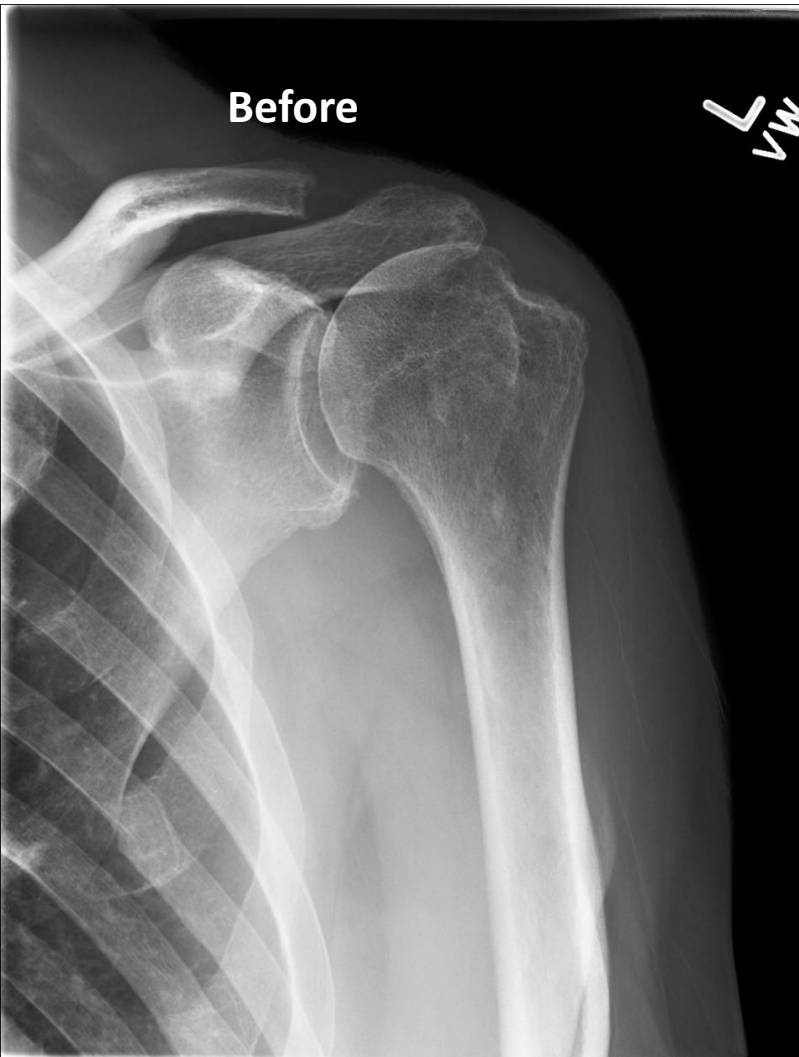Chronic
Rotator cuff
Tear results
In muscle
Fatty degeneration
Which appears
White as muscle
Can no longer
Contract
(supraspinatus
And infraspinatus)





Preoperative 3-Dimensional C.T. Scan planning allows for optimum placement Of Reverse Prosthesis to ensure for maximum stability & range of motion





“Dear Doc, Thank you for taking the time to show me the diagram of my shoulder. You were quite brilliant taking the time to have my shoulder taken care of in every way. IT FEELS SO GOOD TO HAVE MY SHOULDER BACK. It ‘s been two years down with rotator cuff repairs. Other people may just take this surgery for granted and expect you to just do it, but I can really understand your hard work and dedication, and I doubt there are more than a few surgeons in the world gifted with your expertise.”

- L.W., one month after Reverse Shoulder Replacement.